

# **Hepatocellular Carcinoma**

**Lanla F. Conteh MD, MPH**  
**Assistant Professor of Clinical Medicine**  
**Director, GHN Hepatobiliary Tumor Program**  
**Division of Gastroenterology, Hepatology**  
**and Nutrition**  
**The Ohio State University Wexner Medical Center**

## **Outline**

- **Epidemiology of Hepatocellular Carcinoma (HCC)**
- **Prevention and Screening for HCC**
- **Management of HCC**

# Hepatocellular Carcinoma

- Hepatocellular carcinoma (HCC) is the 5th most common malignancy worldwide
- It is the 3rd most common cause of cancer related mortality
- Responsible for 1 million deaths each year
- In the United States, over the past 20 years, the incidence of HCC has increased
- Despite advances in screening and early detection, HCC still has a poor overall 5-year survival rate of 17%

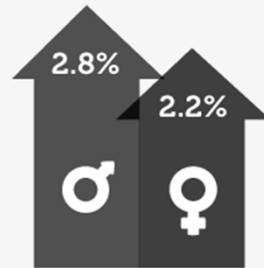
Forner et al., Lancet, 2012

# Epidemiology

- 2016 American Cancer Society's estimates for primary liver cancer and intrahepatic bile duct cancer in the U.S.
  - ~39,230 new cases diagnosed
    - 28,410 in men
    - 10,820 in women
  - ~27,170 people will die from these cancers
    - 18,280 men
    - 8,890 women
- Liver cancer incidence has tripled since 1980
- Liver cancer death rates have been increasing by an average of 3% a year over the last 10 years

# LIVER CANCER DEATHS IN THE U.S. ARE INCREASING AT THE HIGHEST RATE OF COMMON CANCERS

2003 ..... 2012



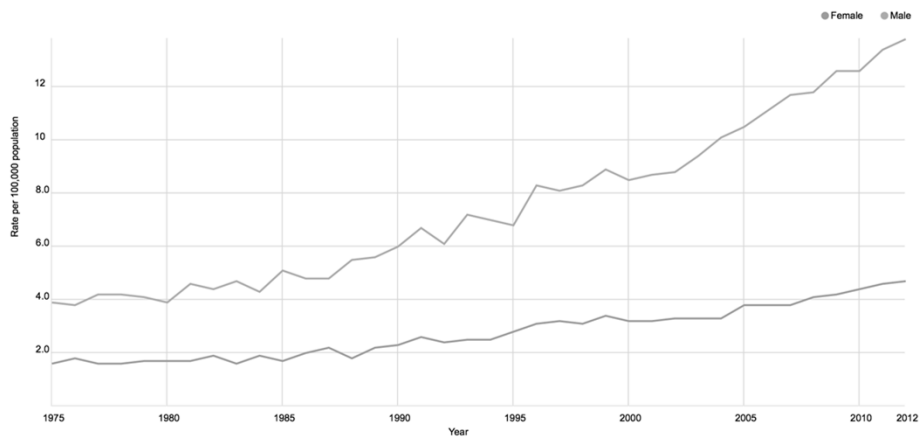
Average Annual Percent Change

[www.seer.cancer.gov](http://www.seer.cancer.gov)

Source: Annual Report to the Nation on the Status of Cancer, 1975-2012

## Trends in incidence rates, 1975-2012

by sex, for liver and intrahepatic bile duct  
Per 100,000, age adjusted to the 2000 US standard population



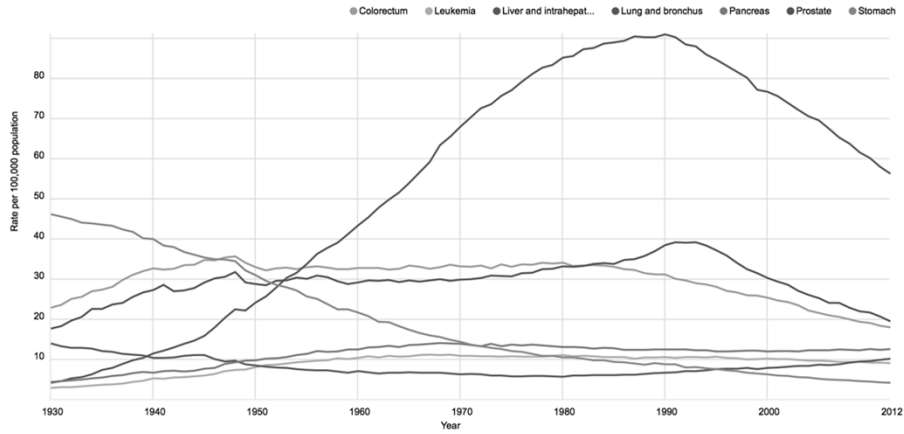
Data Sources: Surveillance, Epidemiology, and End Results (SEER) 9 registries, National Cancer Institute, 2015  
© 2016 American Cancer Society

[CancerStatisticsCenter.cancer.org](http://CancerStatisticsCenter.cancer.org)

## Trends in death rates, 1930-2012

Males

Per 100,000, age adjusted to the 2000 US standard population



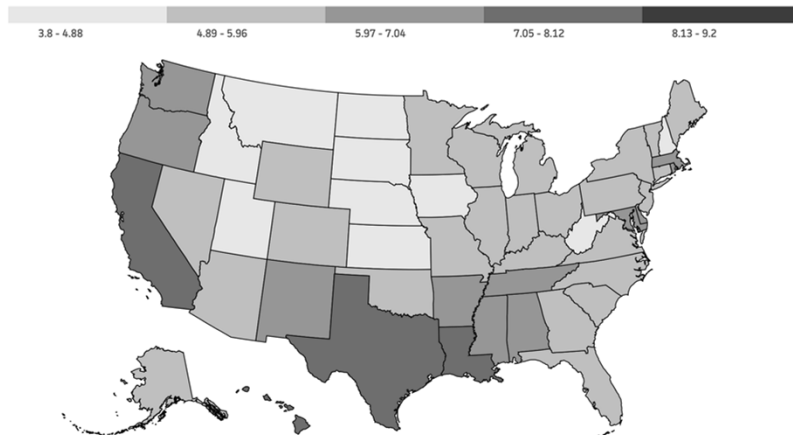
Data Sources: National Center for Health Statistics (NCHS), Centers for Disease Control and Prevention, 2015  
© 2016 American Cancer Society

CancerStatisticsCenter.cancer.org

## Death rates, 2008-2012

by state, for liver and intrahepatic bile duct

Per 100,000, age adjusted to the 2000 US standard population




Data Sources: National Center for Health Statistics (NCHS), Centers for Disease Control and Prevention, 2015  
© 2016 American Cancer Society

CancerStatisticsCenter.cancer.org


### Incidence rates, 2008-2012

by race and ethnicity, for liver and intrahepatic bile duct  
Per 100,000, age adjusted to the 2000 US standard population


#### Asian and Pacific Islander



#### American Indian and Alaska Native




#### Hispanic



#### Non-Hispanic black



#### Non-Hispanic white




Data Sources: North American Association of Central Cancer Registries (NAACCR), 2015  
© 2016 American Cancer Society [CancerStatisticsCenter.cancer.org](http://CancerStatisticsCenter.cancer.org)

### Death rates, 2008-2012

by race and ethnicity, for liver and intrahepatic bile duct  
Per 100,000, age adjusted to the 2000 US standard population

#### American Indian and Alaska Native



#### Asian and Pacific Islander



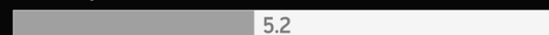#### Hispanic



#### Non-Hispanic black



#### Non-Hispanic white



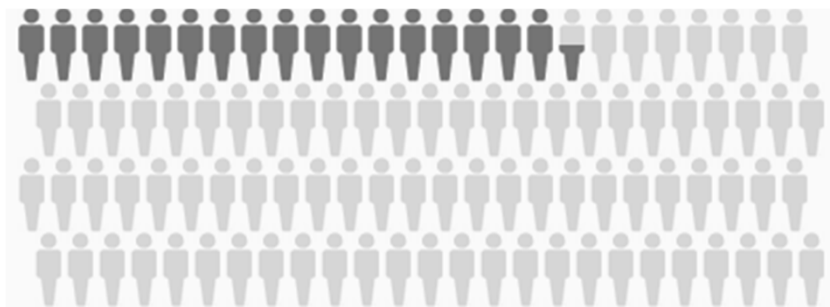Data Sources: National Center for Health Statistics (NCHS), Centers for Disease Control and Prevention, 2015  
© 2016 American Cancer Society [CancerStatisticsCenter.cancer.org](http://CancerStatisticsCenter.cancer.org)

**“The key determinants of health  
actually lie outside the healthcare system”**

**-Sir Michael Marmot**

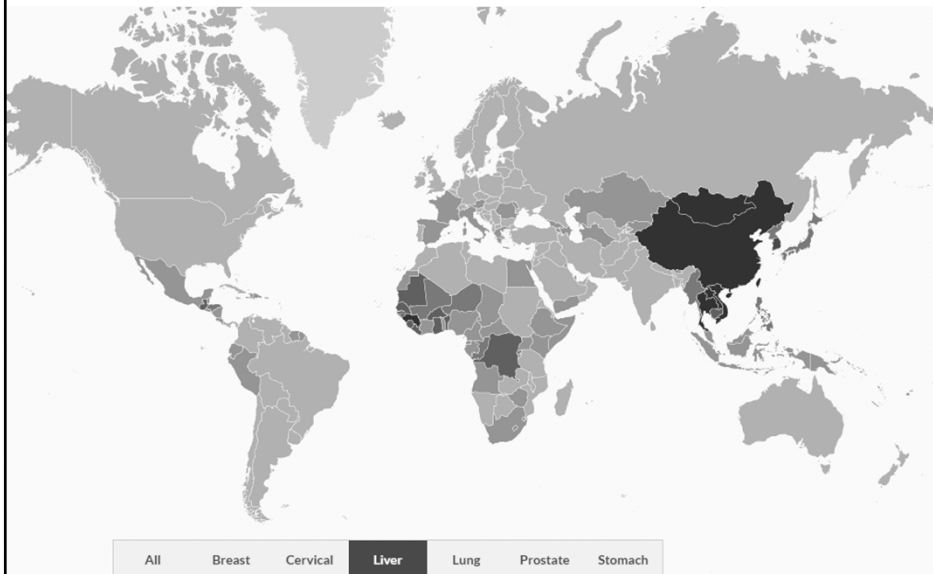
## **5 Year Survival Rate**

• **17.5%**



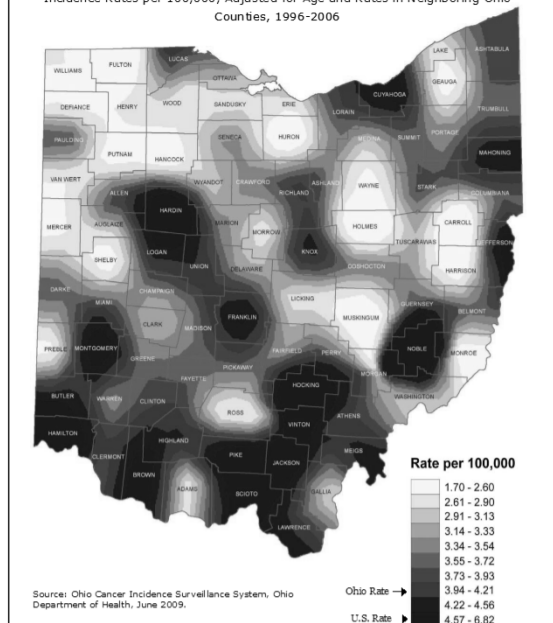
**Seer.cancer.gov 2006-2012 data. Liver and Intrahepatic Bile Duct  
Cancer**

# HCC is a Global Problem



Source: GLOBOCAN 2008 v2.0

Figure 12. Liver and Intrahepatic Bile Duct: Average Annual Invasive Cancer Incidence Rates per 100,000, Adjusted for Age and Rates in Neighboring Ohio Counties, 1996-2006



Source: Ohio Cancer Incidence Surveillance System, Ohio Department of Health, June 2009.

Ohio Cancer Incidence Surveillance System, Ohio Department of Health

# **Prevention**

- **Focus on preventing progression of chronic liver disease to cirrhosis**
  - **Hepatitis B vaccination**
  - **Hepatitis C screening**
  - **Non-Alcoholic Fatty Liver Disease (NAFLD)**
  - **Alcohol**
  - **Autoimmune Hepatitis (AIH)**
  - **Primary Biliary Cirrhosis (PBC)**
  - **Primary Sclerosing Cholangitis (PSC)**

# **SCREENING**



## Clinical Presentation

- Usually no additional symptoms other than those related to chronic liver disease
- High index of suspicion in patients with previously compensated cirrhosis who suddenly decompensate
- Alpha-fetoprotein (AFP) lacks adequate sensitivity and specificity for effective surveillance and for diagnosis
- Not all tumors secrete AFP
- However, generally accepted that serum levels greater than 500 mcg/L in a high-risk patient is diagnostic of HCC


Lok et al, Gastroenterology 2010;138:493-502  
Forner et al, Hepatology 2008;47:97-104

## Is Surveillance Effective?

- Repeated application of a screening test to an at-risk population
- Detect disease at an earlier stage when potential curative options are available and thus reducing disease-related mortality
- HCC readily lends itself to surveillance
- Randomized control trial in China
  - 18,816 patients with chronic HBV infections randomized to biannual surveillance with ultrasonography + serum  $\alpha$ -fetoprotein (AFP) or no surveillance

Zhang BH, Yang BH, Tang ZY. Randomized controlled trial of screening for hepatocellular carcinoma. *J Cancer Res Clin Oncol* 2004;130:417-422.  
Trevisani F, Santi V, Gramenzi A, Di Nolfo MA, Del Poggio P, Benvegnù L, et al.; for Italian Liver Cancer Group. Surveillance for early diagnosis of hepatocellular carcinoma: is it effective in intermediate/advanced cirrhosis? *Am J Gastroenterol* 2007;102:2448-2457.

**Table 3** Outcome of screening

	Screening group	Control group
Person-years in the study	38,444	41,077
HCC occurrence		
No. of cases	86	67
Total incidence(per 100,000)	223.7	163.1
Rate ratio (95% CI)	1.37(0.99, 1.89)	
Deaths from HCC		
No. of death	32	54
Total mortality(per 100,000)	83.2	131.5
Rate ratio (95% CI)	0.63(0.41, 0.98)	

Zhang, BH., Yang, BH. & Tang, ZY. J Cancer Res Clin Oncol (2004) 130: 417.  
<https://doi.org/10.1007/s00432-004-0552-0>

## Why Screen?

- **Symptomatic advanced-stage HCC has dismal outcomes**
  - **5-year life expectancy < 10%**
- **In comparison, HCC identified before the onset of symptoms is more amenable to treatment**
  - **5-year survival rates greater than 50% for both resection and liver transplantation**

Bruix J, Sherman M. Management of hepatocellular carcinoma: an update.  
*Hepatology* 2011;53:1020–1022

## **AASLD: Screening Guidelines**

- **The recommended imaging screening interval is 6 months with ultrasound +/- AFP**
- **Screen patients with cirrhosis and those with chronic hepatitis B with or without cirrhosis**

## **Who to Screen?**

- **Asian men hepatitis B carriers > 40 years**
- **Asian women hepatitis B carriers > 50 years**
- **Hepatitis B carrier with family history of HCC**
- **Patients with HBV and cirrhosis**
- **Africans and North American Blacks with hepatitis B**
- **All patients with cirrhosis**

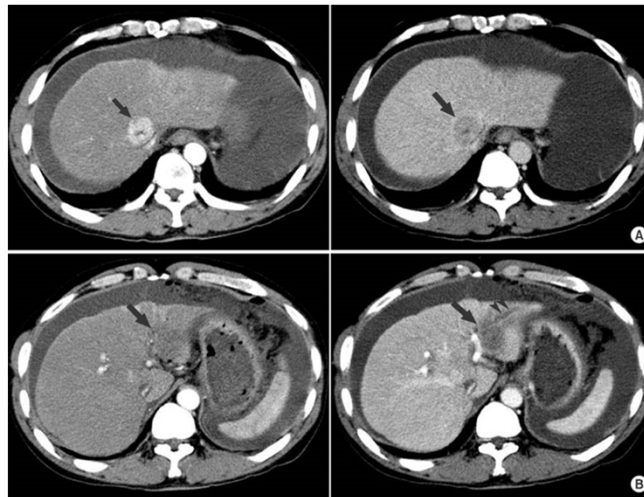
# DIAGNOSIS

**A 53 year old man with cirrhosis due to hepatitis C presents to your office for evaluation and consideration of treatment. As part of the evaluation, you order laboratories which show a platelet count of 72 K/uL, serum bilirubin of 1.2 mg/dL, albumin of 3.7 g/dL. AFP is 27.9 ng/mL. Ultrasound shows a small liver with a 2.1 cm lesion in the right lobe, splenomegaly, and no ascites. Which of the following is the next best step in managing this patient?**

- A. Refer for liver transplantation**
- B. Repeat ultrasound in 3-6 months**
- C. Biopsy of the 2.1 cm lesion in the right lobe**
- D. Radio frequency ablation of the 2.1 cm lesion in the right lobe**
- E. Contrast enhanced computerized tomography of the liver**

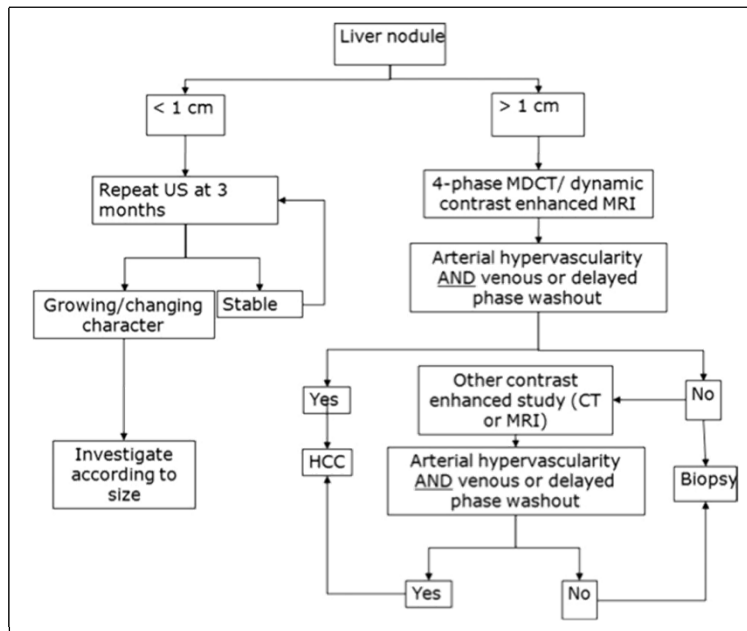
# Diagnosis

- **Diagnosis should be based on imaging techniques and/or biopsy**
- **Multiphase Imaging: intense arterial uptake followed by “washout” of contrast in the venous-delayed phases**



Kang DB, Kim SH, Byun SJ, Oh JT, Park WC, Kim KD, Jo HJ, Lee JK. Metastatic Small Bowel Perforation Caused by Intrahepatic Cholangiocarcinoma in a Patient with Combined Hepatocellular-cholangiocarcinoma. J Korean Surg Soc. 2009 Aug;77(2):138-142. <https://doi.org/10.4174/jkss.2009.77.2.138>

(CC BY-NC 3.0)



Soldera, Jonathan. (2016). Diagnostic and Therapeutic Approaches to Hepatocellular Carcinoma: Understanding the Barcelona Clinic Liver Cancer Protocol. Clinical Medicine Insights: Gastroenterology. 9. 67. 10.4137/C.Gast.S30190.

Image - CC BY-NC 4.0

# TREATMENT

## **Liver Directed Therapy**

- **Liver Transplantation**
- **Resection/Hepatectomy**
- **Percutaneous Ablation (RFA)**
- **Transarterial Chemoembolization (TACE)**
- **Radioembolization: Yttrium<sub>90</sub>**
- **Stereotactic Body Radiation Therapy (SBRT)**

## **Determining Best Therapy**

- **Underlying liver dysfunction/hepatic reserve**
  - **MELD Score/Child-Turcotte-Pugh score**
- **Stage of disease at presentation**
  - **Tumor burden, size, location**
- **Extrahepatic spread, portal vein invasion**
- **Co-morbid conditions**

## Goals of Locoregional Therapy

- Prolong survival by inducing tumor cell death and necrosis
- Slow the progression of tumors to reduce pretransplantation dropout rates
  - Keep Milan within Milan
- Downstage tumors to meet transplantability criteria
  - From UCSF into Milan

A 40-year-old male with chronic HBV infection is referred for management of a hypervascular liver lesion, identified on multiphase CT of the abdomen. The lesion measures 2.5 cm in maximum diameter, is present in the left lateral lobe (segment 2), enhances brightly on the arterial phase, and has a washout; eventually becoming isointense with the rest of the liver on the portal venous phase of the scan. No ascites is seen. The liver contour is smooth and spleen size is normal. The portal vein is patent and no intra-abdominal collaterals are seen on imaging. The patient has been on entecavir antiviral therapy for HBV infection for the past year and serum HBV DNA is undetectable. He is asymptomatic. On exam, he appears well nourished with a normal BMI. There is no scleral icterus. Liver and spleen are not palpable. He has no lower extremity edema. Neurologic exam is normal. Labs tests including INR, albumin, platelet count, creatinine, and total bilirubin are normal. Serum AFP level is 200 ng/ml. What is the best next step in management of this patient?

- A. Ultrasound guided biopsy of the liver lesion
- B. Trans-arterial chemoembolization (TACE) of the liver lesion
- C. Sorafenib
- D. Laparoscopic resection of the liver lesion
- E. Left-sided Portal Vein Embolization



# Surgical Resection

- Potentially curative in patients with adequate liver functional reserve
- Ideal patient
  - Solitary HCC confined to the liver
  - No radiographic evidence of invasion of the hepatic vasculature
  - No evidence of portal hypertension
  - Well-preserved hepatic function
  - No cirrhosis or Child-Pugh class A cirrhosis

## Assessing Surgical Risk with Cirrhosis

- CPT useful in assessing global liver function, however, significant heterogeneity among Child-Pugh class A patients
- MELD can help select ideal candidates
- Patients with a preoperative MELD >10 have 90-day mortality rates approaching 15% to 20%
- Noninvasive, indirect measures of portal hypertension
  - Platelet count of  $\leq 100$  used as surrogate for significant portal hypertension
- Tumor-specific factors in determining the suitability of hepatectomy for HCC include tumor size, tumor number, and presence of vascular invasion

Mailhe SK, Kneuer PJ, Kooby DA, Scoggins CR, Weber SM, Martin RC 2nd, et al. Importance of low preoperative platelet count in selecting patients for resection of hepatocellular carcinoma: a multi-institutional analysis. *J Am Coll Surg* 2011;212:638-648; Pawlik TM, Poon RT, Abdalla EK, Zorzi D, Ikai I, Curley SA, et al. Critical appraisal of the clinical and pathologic predictors of survival after resection of large hepatocellular carcinoma. *Arch Surg* 2005;140:450-457; discussion 457-458.

**66year old man with well compensated cirrhosis secondary to alcohol with continued use. He has a history of AAA repair, AV replacement, 3v CAD and redo aortic valve replacement. Presented with 3 days of worsening progressive shortness of breath, elevated troponins, diaphoresis. He was treated for NSTEMI and underwent PCI and placement of bare metal stent. Currently on Plavix. Underwent multiphase CT scan on presentation and found to have solitary liver mass measuring 2.1cm with arterial enhancement, delayed phase washout.**

## **Percutaneous Ablation**

- **Destruction of tumor cells achieved by injection of chemical substances (ethanol, acetic acid, or boiling saline) or by modifying the temperature (radiofrequency, microwave, laser, cryotherapy)**
- **Radiofrequency ablation (RFA) should be the first choice for local ablation**
- **Usually performed under ultrasound guidance**

# **Radiofrequency Ablation (RFA)**

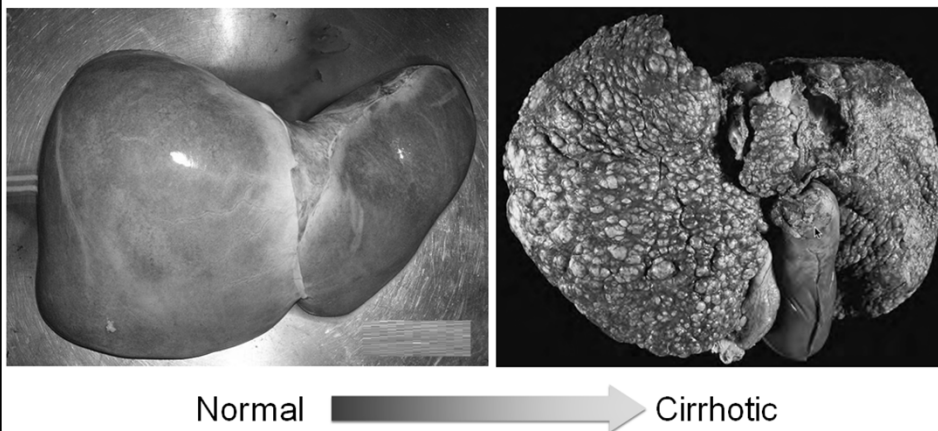
- **Needle conducts a high-energy electrical current into the tumor**
- **Best outcomes are in patients with a single tumor <4 cm in diameter**
- **Well validated and utilized by many centers**
- **Efficacy assessed by multiphase imaging 1 month after therapy**

Bruix J, Sherman M, Llovet JM, Beaugrand M, Lencioni R, Burroughs AK, Christensen E, et al. Clinical management of hepatocellular carcinoma. Conclusions of the Barcelona-2000 EASL conference. European Association for the Study of the Liver. J Hepatol 2001;35:421-430.

**59 year old man with cirrhosis secondary to hepatitis C and alcohol. HCV treated with antiviral therapy, GT1A with SVR. Cirrhosis decompensated by hepatic encephalopathy. Presented with new onset ascites and abdominal pain. Abdominal CT was done which showed an arterial enhancing lesion within lateral segment of left lobe with delayed phase washout and pseudocapsule measures 2.6 x 1.8cm. AFP 7.5ng/ml. MELD-Na score 15. RFA performed with good tumor response. Liver transplant evaluation completed; listed for OLTx.**

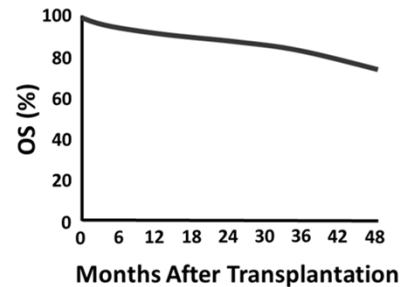
# Liver Transplantation

- Liver Transplantation is now accepted as the best curative therapy for Stage II HCC
- Provides complete oncologic resection and correction of the underlying liver disease



# Total Hepatectomy with Liver Transplantation for Early-Stage HCC

- Inclusion criteria (N=48)
  - Unresectable HCC
  - Staging criteria
    - Single lesion < 5 cm or
    - < 3 lesions, each < 3 cm
- Following liver transplantation,
  - Actuarial survival at 4 yrs: 75%
  - Recurrence-free survival at 4 years: 83%



Mazzaferro V, et al N Engl J Med. 1996;334:693-699

## Milan vs. UCSF

- |  |   |
|--|---|
| <ul style="list-style-type: none"> <li>• <b>Milan Criteria</b> <ul style="list-style-type: none"> <li>• Based on tumor size and number</li> <li>• Stage II HCC</li> <li>• 1 lesion <math>\leq</math> 5 cm</li> <li>• 2-3 lesions <math>\leq</math> 3 cm</li> </ul> </li> </ul> | <ul style="list-style-type: none"> <li>• <b>UCSF Criteria</b> <ul style="list-style-type: none"> <li>• Extended criteria based on tumor size and number</li> <li>• 1 lesion &lt; 6.5 cm</li> <li>• 2-3 lesions &lt; 4.5 cm</li> <li>• Total tumor diameter &lt; 8 cm</li> </ul> </li> </ul> |
|--|---|

# MELD Exception Points

- To give patients with Stage II HCC equal opportunity for transplantation
- Initially given additional points aimed at matching the risk of death in endstage cirrhosis
- Too high a priority was given to HCC patients - unfair to patients without cancer
- Has undergone several iterations
- Most recent: Can only start accumulating exception points after being on the waitlist for 6 months. Awarded 22 points at 6 months, then 10% point increase every 3 months thereafter
- Allows time to assess tumor biology

Bruix and Sherman, Hepatology, July 2010  
Freeman RB, Wiesner RH, Edwards E, Harper A, Merion R, Wolfe R. Results of the first year of the new liver allocation plan. Liver Transpl 2004;10:7-15

# Liver Transplantation

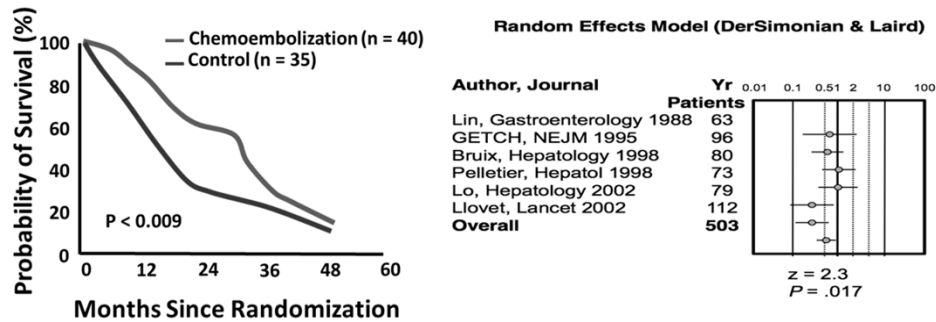
- **Advantages**
  - Definitive management of not only HCC but also underlying liver disease
- **Disadvantages**
  - Long waiting time for donor organs
  - Lifelong immunosuppression
- **Living Donor**

**61year old man with history of hypertension, DM II, hyperlipidemia, obesity. No known history of underlying liver disease. Recently presented with hematemesis secondary to esophageal variceal hemorrhage. Abdominal MRI showed nodular liver with 3 hypervascular lesions in the right hepatic lobe measuring 1.8cm, 2cm, 2.7cm. Characteristic of HCC. MELD-Na 7, ALT 26, AST 32. AFP 14ng/ml. Portal vein is patent. TACE recommended.**

## **Transarterial Chemoembolization (TACE)**

- **HCC gets majority blood supply from hepatic artery**
- **Used most often for the treatment of large unresectable HCCs**
- **Also used commonly as "bridging therapy" prior to transplant**
- **Agents: Doxorubicin, Mitomycin C, Cisplatin**

# TACE Prolongs Survival in Unresectable HCC



Llovet J, et al. Lancet. 2002;359; 1734-1739.

Llovet J, et al. Hepatology. 2003;37:429-442.

## TACE: Contraindications

- **Absolute contraindications**
  - Absence of hepatopetal blood flow (portal vein thrombosis), biliary obstruction
- **Relative contraindications:**
  - Serum bilirubin >3 mg/dL
  - Tumor burden involving >50% of the liver
  - Cardiac or renal insufficiency



## **Radioembolization: Y90**

- **Intra-arterial injection of small microspheres loaded with the radionuclide yttrium-90 (Y<sub>90</sub>)**
- **Delivery of the microspheres into the feeding vessels of the tumor leads to their settling in the tumor itself without affecting the vasculature**
- **Beta-emitting particle that has a localized radius of radiation delivery (2.5–11.0 mm)**
- **1/2-life 60 hours**

## **Y<sub>90</sub>**

- **Advantages:**
  - **Low toxicity**
  - **Potential to treat patients with significant tumor burden**
  - **Relatively limited side effects**
  - **Has been used with PVT**
- **Disadvantages:**
  - **High cost**
  - **The costs approached \$17,000 for TACE versus \$31,000 or \$48,000 for unilobar or bilobar radioembolization**
  - **Requires at least two abdominal angiographies**
  - **Certain anatomical constraints (eg, pass-through of the radioactive material to the lung in some patients with shunting)**

**61year old man with h/o HCV and IVDU. Clean since 2008. He is treatment naive, GT1B. Underwent screening abdominal ultrasound in preparation for antiviral therapy and was found to have 2 masses in the right lobe concerning for HCC with AFP of 7,000. Underwent multiphase CT scan which showed cirrhosis with bilobar multifocal HCC with portal vein thrombus and multiple matted, enlarged upper retroperitoneal nodes concerning for metastasis. MELD-Na 11, bilirubin 1.2mg/dl. Sorafenib recommended.**

## **Molecular Targeted Therapy**

- **HCC considered to be a relatively chemotherapy-refractory tumor**
- **High rate of expression of drug resistance genes**
- **Challenging to gauge benefit from chemotherapy in patients with advanced HCC**
- **Survival is most often determined by degree of hepatic dysfunction**
- **Systemic chemotherapy is usually not well tolerated by patients with significant underlying hepatic dysfunction**

# SHARP TRIAL

- Placebo-controlled, phase III trial
- Patients with Child-Pugh A and HCC compatible with stage C disease by the BCLC system
- Median survival nearly 3 months compared to placebo 10.7 months vs. 7.9 ( $p < 0.001$ )
- Largely stabilized the tumor by delaying tumor progression → mainly acts as a cytostatic agent
- Led to approval by regulatory agencies in 2007 (USA and EU)

Llovet JM, Ricci S, Mazzaferro V, Hilgard P, Gane E, Blanc JF, et al. Sorafenib in advanced hepatocellular carcinoma. *N Engl J Med* 2008;359:378–390

## Combination Therapy

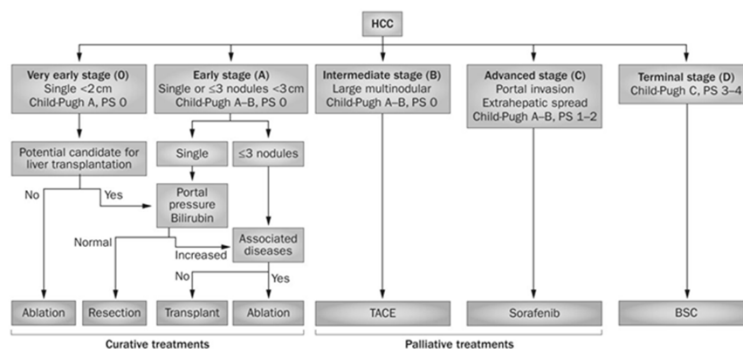
- SPACE TRIAL
- Phase II randomized, double blind, placebo-controlled study of Sorafenib or placebo in combination with TACE with doxorubicin-eluting beads (DEB-TACE)
- 307 patients with unresectable intermediate-stage HCC and Child-Pugh A cirrhosis
- Statistically significant advantage of sorafenib over placebo in time to progression (TTP) [median TTP: 169 days, HR: 0.797 (95% CI, 0.588, 1.080;  $p = 0.072$ )]

Pawlik TM, Reyes DK, Cosgrove D, Kamel IR, Bhagat N, Geschwind JF. Phase II trial of sorafenib combined with concurrent transarterial chemoembolization with drug-eluting beads for hepatocellular carcinoma. *J Clin Oncol* 2011;29:3960-3967  
Lencioni RL, Llovet JM, Han G, Tak W-Y, Yang J, Leberre M-A, et al. Sorafenib or placebo in combination with transarterial chemoembolization (TACE) with doxorubicin-eluting beads (DEBDOX) for intermediate-stage hepatocellular carcinoma (HCC): phase II, randomised, double-blind SPACE trial. *J Clin Oncol* 2012;30( suppl 4). Abstract LBA154.

# Summary

- Incidence and death rate of HCC is increasing
- Screening is vital
- For patients with cirrhosis and portal hypertension, mainstay of therapy should be transplant if appropriate
- LRT can be used to bridge patients to transplant
- Some liver directed therapies can be combined or used in sequence

## BCLC Staging and Treatment Strategy



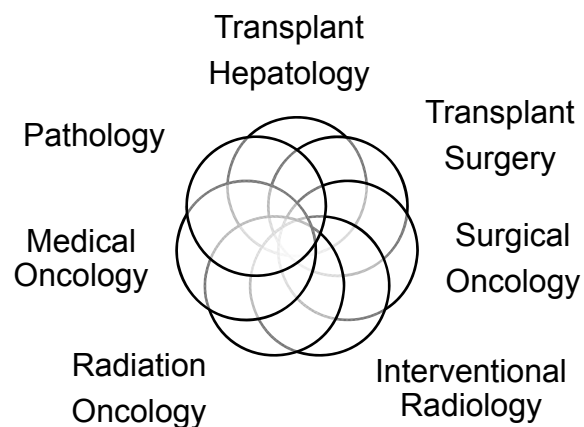
Forner, A. *et al.* (2014) Treatment of intermediate-stage hepatocellular carcinoma *Nat. Rev. Clin. Oncol.* Doi: 10.1038/nrclinonc.2014.122

# What OSU Offers

- **Hepatology Clinics**
  - Main Campus, CPE, Hilliard, UA
- **Satellite Grand Rounds**
- **Multidisciplinary Liver Tumor Clinic - Martha Morehouse**
- **Liver Tumor Board**



## Multidisciplinary Team



***October is***  
**Liver Cancer**  
**Awareness Month**



**Fight - Support - Advocate**